

University of Allahabad
Department of Zoology
Allahabad (India)

A. N. CHATTORAJ & V. P. SHARMA

Changes induced in the blood cells of insects by the application of certain organic insecticides

With 7 textfigures

The present studies were undertaken to study changes in the blood cells of certain insects after the application of organic insecticides in order to establish the haematological changes. The insecticides are: DDT (p, p'), Dieldrin, Dimecron, Lindane, Methoxychlor, and Parathion, and the insects are the adult cockroaches *Periplaneta americana*, nymphs of grasshoppers *Poecilocerus pictus*, and the larvae of Saturniid moth *Attacus recini*.

TAREEVA & NENJUKOV (1931) have described the blood picture of *Calliptamus italicus* after sodium arsenate and sodium fluoride poisoning. PILAT (1935) has described the blood picture of *Locusta migratoria* with intestinal poisoning of sodium arsenite and sodium silicofluoride at various intervals.

YEAGER & MUNSON (1942) studied extensively the effects of Nicotine, Bentonite, Nicotine Peat, Rotenone, Pyrethrum, Phenothiazine, Barium calcium arsenate, Sodium fluoaluminate, Sodium fluoride, Mercuric chloride, Calcium arsenate, Calcium arsenite, Arsenic trioxide, Paris green, and Lead arsenate on the blood cells of *Prodenia eridania* larvae. They observed haematological changes as: the generative cytoplasmic changes consisting of apparent cellular swelling, disruption of and decrease in visibility of normal structures, decrease or loss of blood cell glycogen, formation of broad pseudopodia or cytoplasmic buldges, plastid formation, excessive vacuolization, and raggedness, and the nuclear degeneration involved distortion, raggedness, loss or disruption of normal structure, achromophilia, assumption of more or less peripheral position, fragmentation, pycnosis, and extrusion. YEAGER & MUNSON classified haematological changes in three categories following the poison administration (1) Passive-active transformation and cell agglutination. (2) Regenerative alterations and (3) Degenerative changes. TOUMANOFF & LAPIED (1950) described the blood cell changes in *Galleria* after direct contact of haemocytes to DDT in vitro. They claimed that DDT brought about lysis of haemocytes in vitro, that haemocytes contained phagocytized crystals of DDT, and haemocytes neutralized the action of DDT, and contact of DDT brought about marked changes in differential counts. JONES & TAUBER (1954) have described the blood cell counts, and abnormal blood picture of *Tenebrio molitor* larvae with the administration of DDT, sodium fluoride, nicotine and other substances.

Material and Method

Insects required for the experiment were reared in laboratory for the facility of continuous supply. The insecticides employed in this study were made into different concentrations by dilution in their respective solvents and were applied with the aid of a micro-applicator. A known quantity of the insecticide was applied topically on the pronotum of the cockroaches and the grasshoppers, and by injection to the 3rd stage larvae of *Attacus recini*; and in all the cases doses were sufficiently high, as to cause death within 12 hours time (see Table 1). The treated insects were left in the cages and petri dishes provided with sufficient food and water. Moribund insects were collected and their blood was taken out amputating at the antennae of the cockroaches and grasshoppers, and prolegs of the larvae with scissors. The blood was heat fixed at 58–60° C for 3 to 5 minutes. Thin smears of blood were prepared on the slides, dried in air, stained with any one of the following stains Wright's or Leishman's or Haematoxylin and eosin and mounted in Canada bassam. Untreated and control experiments were run simultaneously.

Observations

The type of blood cells and their number varies greatly with the insect. The different type of cells found in the insect's blood have a uniform boundary, are evenly stained, their nuclei lie in the centre, and have regular outlines (Fig. 1). The changes induced by different insecticides are more or less of the same type excepting that the intensity varies with the insecticide and the insect. Following descriptions are of poisoned haemocytes only.

DDT (p, p')

With the application of this insecticide the cytoplasm of the blood cells is faintly stained and the pathological condition of cells is not as intense as we find with other poisons more especially with organophosphates. Only few cells are affected by the poison and most of the cells remain unaffected. However, the affected blood cells of grasshoppers and cockroaches show the following changes: cell agglutination, contracted cytoplasm, plastid formation, slight surface irregularities, cytoplasmic raggedness; and the nuclei appear swollen, dislocated, extruded, and hypertrophied. The haematological changes in the *Attacus* larvae are: cell agglutination, contraction, cell wall foldings, plastid formation, cytoplasmic raggedness, surface irregularities, fusiform cells become round, nuclei swollen, hypertrophied and visible (Fig. 2).

Dieldrin

In the haemolymph of grasshoppers and cockroaches the blood cells changes are noted as: decrease in the visibility of cytoplasm, cell agglutination, plastid formation, irregularities in shape of haemocytes, formation of microhaemocytes and megalohaemocytes, and the nuclear degenerations are observed as: irregularities in shape, distortion, extrusion, and hypertrophy. In *Attacus* larvae the haematological changes are observed as: contraction of cytoplasm, cell wall foldings, un-

evenly stained cytoplasm, formation of plastids, and the nuclei are visible and hypertrophied. As compared with the grasshoppers and cockroaches the visibility of cytoplasm is not reduced in the blood of *Attacus* (Fig. 3).

Dimecron

Treatment of grasshoppers and cockroaches with Dimecron cause the following haematological changes: cell agglutination, formation of plastids, microhaemocytes, megalohaemocytes, and abnormal haemocytes (poikilohaemocytes); and the damage to the nuclei has been recorded as: distortion pycnosis, atrophy, hypertrophy, and extrusion. Changes observed in the blood cells of *Attacus* larvae are: contraction and decrease in the visibility of cytoplasm, unevenly staining, cell agglutination, cell wall foldings, plastid formation; and the nuclei are ragged, swollen, and hypertrophied. Compared with the grasshoppers and cockroaches, we find that the haemocytes of *Attacus* larvae are more affected (Fig. 4).

Lindane

The application of lindane causes very little haematological changes as compared to other insecticides. The cytoplasm of the blood cells takes a faint stain. In haemocytes of grasshoppers and cockroaches, the pathology is noted as: cell agglutination, blood cells retain their shape and structure and at places only cell wall foldings are observed, there are no plastids, no vacuoles, and certain nuclei become pycnotic. In blood cells of *Attacus* larvae the haematological changes observed are: cell agglutination, foldings of ectoplasm, nuclear swelling, fusiform cells become round, unevenly stained, and plastids are formed. The blood cell changes are intense in *Attacus* larvae (Fig. 5).

Methoxychlor

Action of Methoxychlor on the blood of grasshoppers and cockroaches is manifested as: cell agglutination, formation of plastids, microhaemocytes, and megalohaemocytes; and the cytoplasm is disintegrated. Damage to the nuclei is recorded as: atrophy, hypertrophy, swelling, acquire peripheral positions and lie deeply stained. In *Attacus* larvae, the ectoplasm shows foldings and overlap the nuclei making them invisible, cell agglutination, cytoplasm become granular, formation of plastids, and cytoplasmic buldges give pseudopodial appearance (Fig. 6).

Parathion

Most conspicuous and intense haematological changes are observed with the application of Parathion. Parathion causes decrease in the visibility of cytoplasm of haemocytes. In the haemocytes of grasshoppers and cockroaches the pathology is noted as: cell agglutination, formation of plastids, microhaemocytes, megalohaemocytes, and abnormal haemocytes (poikilohaemocytes), gross irregularities in shape, cytoplasm shrunk, vacuolated, dissolved, disintegrated, certain fusiform cells acquire roundish appearance, and the presence of abnormal granules. The nuclear degenerations are recorded as: pycnosis, hypertrophy, extrusion, raggedness, dislocation acquire peripheral positions, swollen, gross irregularities in shapes, rupture (karyorrhexis), and distortion. In *Attacus* larvae, fusiform cells round up,

the cytoplasm is shrunk, sends out lamellar extensions of cytoplasm giving pseudo-podial appearance, unevenly stained, plastids are formed, cell wall foldings overlap the nuclei and they are hypertrophied (Fig. 7).

Table 1
Details of treatments

Sl. no.	Insecticides	Doses applied to individual insects in micro-grams		
		Cockroaches	Grasshoppers	<i>Attacus</i> larvae
1.	DDT (p, p')	92.70	39.62	8.63
2.	Dieldrin	71.90	25.59	5.86
3.	Dimecron	69.45	26.65	14.30
4.	Lindane	71.95	31.67	9.60
5.	Methoxychlor	69.10	27.34	6.58
6.	Parathion	54.50	24.50	7.45

Table 2
The comparative haematological changes in the blood cells

Sl. no.	Insecticides	Grasshoppers		Cockroaches		<i>Attacus</i> larvae	
		Cytoplasm	Nuclei	Cytoplasm	Nuclei	Cytoplasm	Nuclei
1.	DDT (p, p')	+	++	+	++	++	+
2.	Dieldrin	+	++	+	++	++	+
3.	Dimecron	+	++	+	++	+++	+
4.	Lindane	+	+	+	+	++	+
5.	Methoxychlor	+	+	+	+	++	+
6.	Parathion	+++	+++	+++	+++	+++	++

Discussion

JONES & TAUBER (1954) concluded that certain kinds of pathological haemocytes may be more numerous following administration of poison, these abnormalities are not specific or peculiar for the particular poison used. They have given a classification of abnormal haemocytes, and have presented three categories of induced abnormal blood cells changes. The present findings show that insecticides cause various degrees of haematological changes. The intensity of the pathology varies as much with the insect, as with the insecticide. However, the present study of haematological changes with different insecticides reveals that the changes are of similar general nature and only vary in intensity. This work is in agreement with JONES & TAUBER (1954), that the haematological changes induced in the haemolymph are not specific for a particular insecticide used. The pathological haemocytes described in the text fall in the same classification of abnormal haemocytes reported by JONES & TAUBER, and are in agreement with those abnormal haemocytes reported by other investigators.

The observations show (see Table 2) little haematological changes after the administration of Lindane and Methoxychlor marked changes are observed with the

application of DDT, Dieldrin and Dimecron, and most conspicuous haematological changes are observed after the administration of Parathion.

Further, the authors observed in all affected haemocytes the decrease of visibility of cytoplasm and cell agglutination. In haemocytes of grasshoppers and cockroaches only certain cells undergo pathological changes and the number of such pathologically abnormal cells varies greatly with the insecticide whereas in *Attacus* all haemocytes show pathological abnormalities of same type. These general effects on the blood cell of larvae are probably due to the direct action of insecticides, since the insecticides were applied by injection to the larvae.

The action of insecticides on the blood cells also shows certain abnormalities that are specific to the insect, such formation of microhaemocytes, megalohaemocytes, and abnormal haemocytes (poikilohaemocytes), presence of abnormal granules, vacuolisation, and extrusion of cytoplasm or nuclei or both etc., etc. are observed in grasshoppers and cockroaches. Whereas in the blood cells of *Attacus* larvae, the specific changes are the shrinkage of cytoplasm and formation of cytoplasmic buldges or pseudopodia like structures coming out of the blood cells, and most fusiform cells become round; and changes like vacuolisation, presence of abnormal granules, and extrusion of cytoplasm or nuclei are not observed.

The nuclei of the haemocytes of grasshoppers and cockroaches are put to various kinds of degenerations by their raggedness, rupture (karyorrhexis), atrophy, hypertrophy, pycnosis, vacuolisation, swelling, and extrusion. However, instead of these changes the nuclei of haemocytes of *Attacus* larvae show a there is no vacuolisation and the fusiform cells become round, and damage to the nuclei has been observed as: dislocation, overlapping of the nuclei by cytoplasmic folds, they are deeply stained and hypertrophied.

Acknowledgements

Authors owe thanks to Professor M. D. L. SRIVASTAVA, Head of the Zoology Department for providing the necessary research facilities and to M/s CIBA PHARMA Ltd. for sample of Dimecron.

Summary

Action of DDT (p, p'), Dieldrin, Dimecron, Lindane, Methoxychlor, and Parathion have been studied on the blood cells of cockroaches, grasshoppers, and *Attacus* larvae. The action of insecticides on the blood cells of *Attacus* larvae cause a general shrinkage of cytoplasm, there is no vacuolation and the fusiform cells become round, and the nuclei are variously damaged such as: dislocation, hypertrophy- and cytoplasmic folds overlapping the nuclei. They are deeply stained. In grasshoppers and cockroaches the insecticides cause: the formation of microhaemocytes, megalohaemocytes, abnormal haemocytes, presence of abnormally large granules, and vacuolation; and the damage to the nuclei has been observed as: raggedness, rupture (karyorrhexis), atrophy, hypertrophy, pycnosis, vacuolation, dislocation, swelling, and extrusion.

Zusammenfassung

Die Wirkung von DDT (p, p'), Dieldrin, Dimecron, Lindane, Methoxychlor und Parathion auf die Blutzellen von Schaben, Heuschrecken und *Attacus*-Larven wurde untersucht. Bei den Blutzellen der *Attacus*-Larven rufen die Bekämpfungsmittel einen allgemeinen Zell-

plasmaschwund hervor. Eine Vakuolenbildung tritt nicht ein, die spindelförmigen Zellen werden rund, und die Kerne erleiden verschiedenartige Schäden wie Dislokation, Hypertrophie und eine Überlappung der Kerne durch Zellplasmafalten. Sie werden stark gefärbt. Bei Heuschrecken und Schaben verursachen die Bekämpfungsmittel die Bildung von Mikrohämozyten, Megalohämozyten und abnormen Hämozyten, das Auftreten von abnorm großen Granulen und Vakuolenbildung. An den Kernen wurden folgende Schäden festgestellt: Zottigkeit, Risse (Kernzerfall), Atrophie, Hypertrophie, Verdickung, Vakuolenbildung, Dislokation, Schwellung und Herausdrängung.

Резюме

Исследовалось действие, оказываемое ДДТ (р, р'), дильдрином, димекроном, линданом, метоксихлором и паратионом на кровяные клетки тараканов, кузнечиков и личинки *Attacus*. В кровяных клетках личинок *Attacus* названные средства вызывают в основном атрофию плазмы клетки. Вакуоли не образуются, веретенообразные клетки округляются, а ядра претерпевают различные повреждения, например, смещение, гипертрофию и перекрывание ядер складками плазмы клеток. Они сильно окрашиваются. У кузнечиков и тараканов средства защиты вызывают образование микрогемоцитов, мегалогемоцитов и ненормальных гемоцитов, появление ненормально больших гранул и вакуолей. На ядрах были обнаружены следующие повреждения: ворсинчатость, трещины (распад ядра), атрофия, гипертрофия, утолщение, образование вакуолей, смещение, набухание и выпирание.

References

- ARNOLD, J. W., Effects of certain fumigants on haemocytes of the Mediterranean flour moth, *Ephestia kühniella* ZELL. (Lepidoptera: Pyralidae). Can. Journ. Zool., **30**, 365—374; 1952.
- JONES, J. C. & TAUBER, O. E., Abnormal hemocytes in Mealworms (*Tenebrio molitor* L.). Ann. ent. Soc. Amer., **47**, 428—444; 1954.
- LEPESME, P., L'action externe des arsenicaux sur le Criquet pèlerin (*Schistocerca gregaria* FORSK.). Bull. Soc. Hist. Nat. de l'Afrique du Nord, **28**, 88—103; 1937.
- PILAT, M., The effects of intestinal poisoning on the blood of locusts (*Locusta migratoria*). Bull. Ent. Res., **26**, 283—292; 1935.
- TAREEVA, A. I. & NENJUKOV, D. V., Effect of poisons on normal digestion and the blood of *Calliptamus*. [Russ.]. Bull. Plant Prot., Leningrad, **3**, 39—49; 1931.
- TOUMANOFF, M. C. & LAPLED, M., Action du dichlorophenyltrichloroethane (DDT) sur les chenilles de la fausse teigne des ruches *Galleria mellonella* L. Effect de la temperature. Action sur le sang. Acad. Agr. de France, May 24: 4 pages; 1950.
- YEAGER, J. F. & MUNSON, S. C., Changes induced in the blood cells of the southern armyworm (*Prodenia eridania*) by the administration of poisons. Journ. Agr. Res., **64**, 307—332; 1942.

Explanation of details of photomicrographs

- | | |
|---|---|
| 1 - Untreated haemocytes | 9 - Poikilohaemocytes |
| 2 - Plastid formation | 10 - Thickening of chromatin |
| 3 - Microhaemocytes | 11 - Peripheral condensation of chromatin |
| 4 - Pycnotic nuclei | 12 - Vacuolated haemocytes |
| 5 - Dissoluted cytoplasm | 13 - Foamy cytoplasm |
| 6 - Swollen nuclei | 14 - Surface irregularities |
| 7 - Hypertrophied nuclei | 15 - Fusiform cells tend to become round |
| 8 - Megalohaemocytes (showing only nucleus) | 16 - Extruded nucleus |
| | 17 - Abnormal cellular extensions |

Explanation of figures

A - Haemocytes of *Attacus* larvae

B - Haemocytes of Cockroaches

C - Haemocytes of Grasshoppers

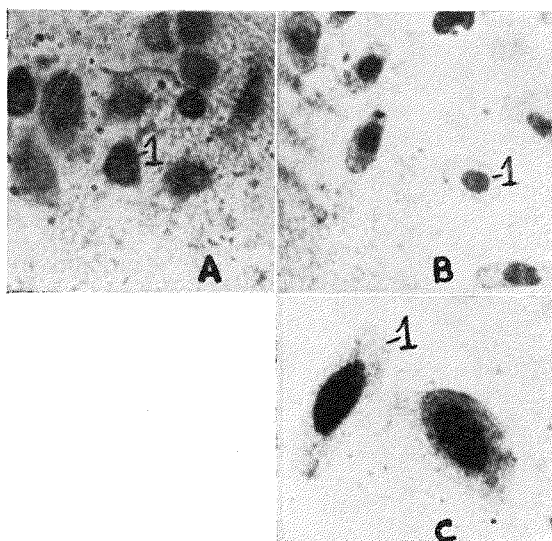


Fig. 1. Haemocytes of untreated insects

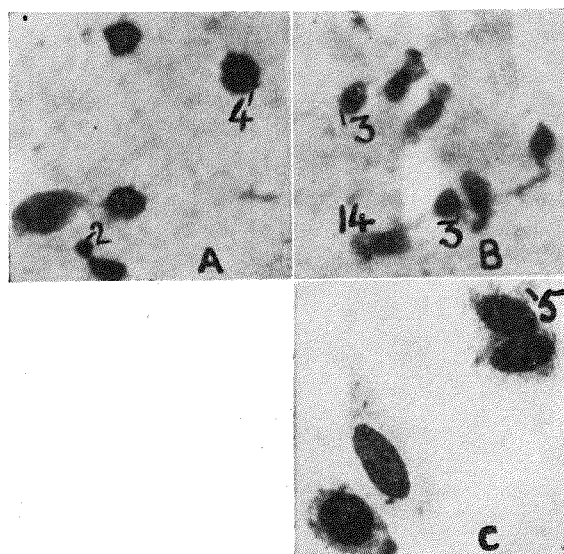


Fig. 2. Haemocytes of DDT treated insects

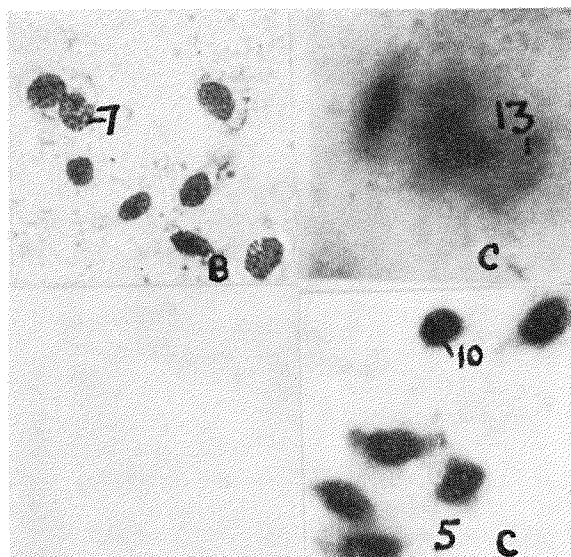


Fig. 3. Haemocytes of Dieldrin treated insects

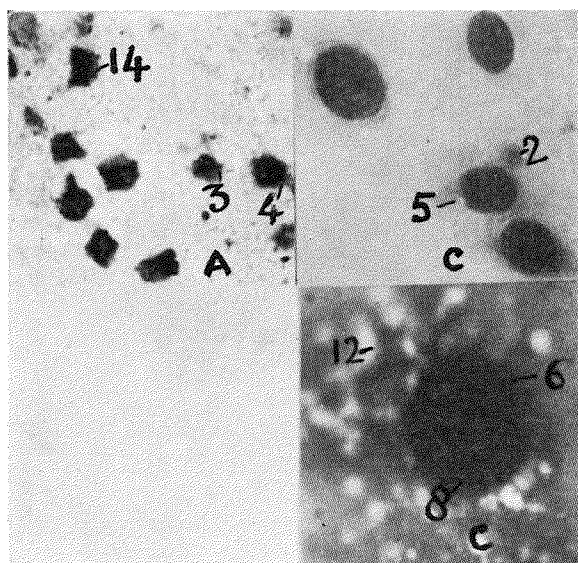


Fig. 4. Haemocytes of Dimecron treated insects

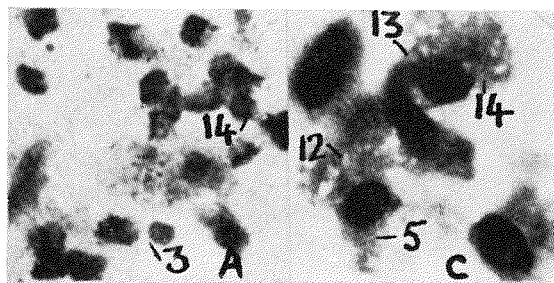


Fig. 5. Haemocytes of Lindane treated insects

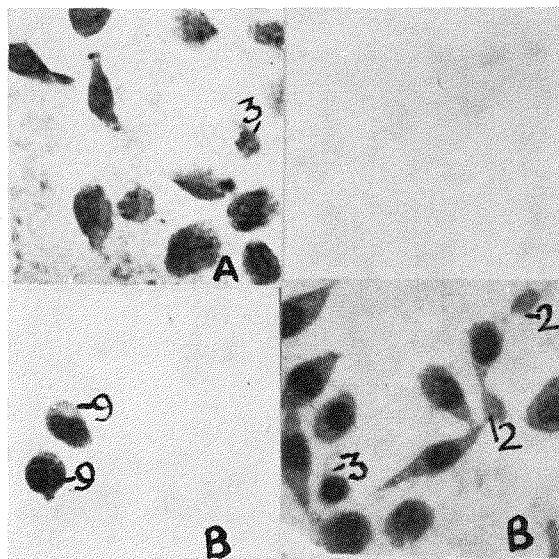


Fig. 6. Haemocytes of Methoxychlor treated insects

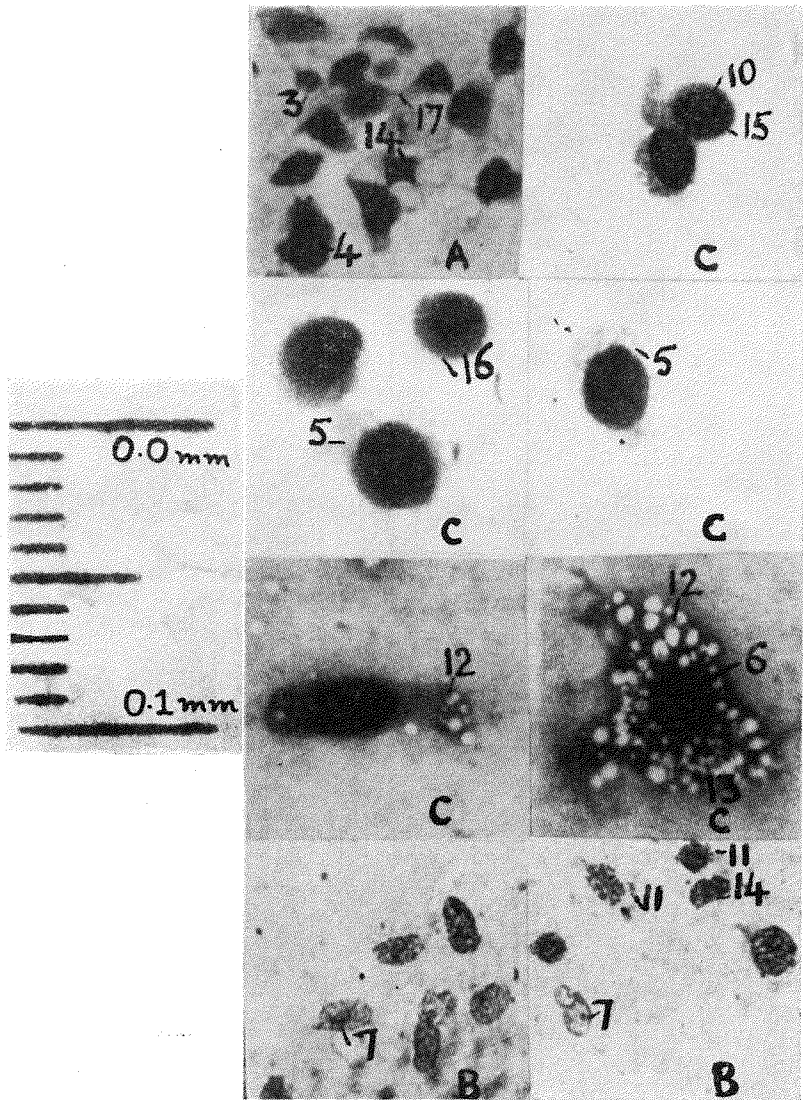


Fig. 7. Haemocytes of Parathion treated insects